Evaluation of Wound Bed Preparation with Monofilament Pad

Ann Taylor, MS, RN, CWOCN
Wound Nurse Consultant Ethica

Conservative sharp debridement is the standard method for removal of slough and loose debris but is not always available due to scope of practice. Modalities like ultrasonic debridement require equipment and supplies that are not always readily accessible. Effective topical therapies take longer than methods that immediately remove debris.

OBJECTIVES

Bedside debridement challenges include scope of practice, cost, and provider time. Discomfort from infection and anticoagulation therapy are often barriers to non-advanced providers. Sharp debridement is not always the best option for wound bed preparation and wound hygiene.

METHODOLOGY

A disposable debriding pad or lolly consisting of monofilament polyester fibres was used for wound bed preparation when slough and /or scaling was present. The device was used to gently debride the necrotic tissue or scales for 30 seconds to 2 minutes, dependent upon patient tolerance.

RESULTS

Patients #1-4 were treated with device for 2 minutes; patients #5 and #6 for 30 seconds x 2 due to tenderness in wound bed. Patient #1, #2 and #3, neuropathic feet: wound beds visibly cleaner, #2 loosened for sharps debridement; Pt # 3 scaling markedly improved and wound bed well defined; Pt #4 on diprovan, 100% dense adherent slough visibly disrupted bed, 15% clean after treatment; Pt #5 scaling resolved and wound bed beefier and hydrated; Pt #6 wound bed 50% slough removed, and some sharps debridement was able to be completed.

Pt #1 Pre-Pad

Pt #1 Post Pad

Pt #2 Pre Lolly

Pt #2 Post Lolly

Pt #3 Pre-Pad

Pt 3# Post Pad

Pt # 4 Pre-Pad

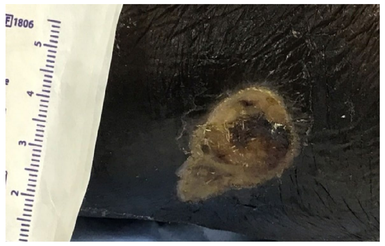

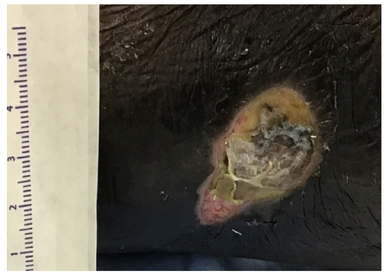

Pt #4 Post Pad

#Pt 4, 2 weeks post Pad and honey gel 3 x week

Pt #5 Pre-Pad

Pt #5 Post Pad

Pt #5 1 week post PAD

Pt #6 Pre & post Pad

CONCLUSION

Skin scaling: Scales removed atraumatically and comfortably.

Debridement: when discomfort was present well tolerated with short rest period; appears to break up the density of the tissue surface for penetration of topicals; some slough loosened up well enough to sharp debride; well tolerated in neuropathic patients.

Bleeding: none associated with use.

No scope of practice issue makes this a safe, inexpensive and effective debridement option for multiple care settings.

REFERENCES

https://www.lohmann-rauscher.com/us-en/products/wound-care/debridement/debrisoft/

ACKNOWLEDGEMENT & CONTACT

Research completed while employed at Wellstar Health System

Ann Taylor: kahlwocn@charter.net

RESEARCH POSTER PRESENTATION DESIGN © 2015
www.PosterPresentations.com